




Available online at
 ScienceDirect
www.sciencedirect.com

Elsevier Masson France

www.em-consulte.com/en



ORIGINAL ARTICLE

Components anteversion in primary cementless THA using straight stem and hemispherical cup: A prospective study in 91 hips using CT-scan measurements

O. Reikerås*, R.B. Gunderson

Orthopaedic and Radiological Departments, Oslo University Hospital, Rikshospitalet, 0027 Oslo, Norway

Accepted: 22 February 2011

KEYWORDS

Arthroplasty;
Component
positioning;
CT-scan;
Hip;
Measurement

Summary

Background: The recommended range of anteversion of the components in total hip arthroplasty (THA) is between 10 and 30°, but the intraoperative estimation of these versions may be inadequate.

Hypothesis: The components anteversion in primary cementless THA using straight stem and hemispherical cup is not significantly different from the native anteversion of the hip joint.

Objectives: To evaluate in a prospective manner the range of anteversion currently achieved in cementless THA.

Patients and methods: Five senior surgeons operated 91 patients with primary cementless THA. We used a straight press fit stem and a hemispherical press fit cup. We aimed to obtain femoral anteversion of 10 to 30°, acetabular anteversion of 10 to 30° and a global combined anteversion of 25 to 55°. Cup position was checked with an impactor-positioner, and stem position was determined with the knee flexed 90°. In all cases we used elevated liners and 28 mm diameter ceramic heads. At 3 months postoperatively the component versions were measured using a General Electric LightSpeed Pro 16 (Milwaukee, WI, USA) with the patient in supine position.

Results: Femoral component measurements ranged from 17° of retroversion to 60° of anteversion with a mean of $23.0 \pm 11.8^\circ$. Similarly, acetabular component version ranged from 28° of retroversion to 46° of anteversion with a mean of $18.5 \pm 13.7^\circ$. There were no correlations to the native femoral and acetabular versions. Only 55 hips (60.4%) were within the accepted range of 25 to 55° of combined anteversion, but none of the cases dislocated during a follow-up of 2 years.

* Corresponding author. Tel.: +47 23076013; fax: +47 23076010.
E-mail address: olav.reikeras@rikshospitalet.no (O. Reikerås).

Conclusion: In cementless THA with our operative technique, the intraoperative estimation of femoral and acetabular anteversion, in many cases, resulted to be inadequate in relation to the intended range of 10 to 30° of anteversion.

Level of evidence: Level III, prospective diagnostic.

© 2011 Published by Elsevier Masson SAS.

Introduction

Accurate placement of the femoral and acetabular components has been considered as a prerequisite for successful total hip arthroplasty (THA) [1–4]. The optimal position of the components has been studied by many authors, and the stem and cup should provide a mean combined anteversion of approximately 37° (range, 25 to 50°) to avoid impingement and/or dislocation [5–8]. In cementless THA the surgeon has poor control of the anteversion of a straight femoral stem since it tends to be dictated by the anteverted or retroverted shape of the proximal femur. However, there is little published information about the component placements in cementless THA, and only one study has compared the component versions with the native versions [9].

Component version in THA has in general been assessed from plain radiographs. This relies on accurate and reproducible patient positioning and complex formulas and mathematical tables [10,11]. Therefore plain radiographic methods are of limited use. Computed tomography (CT) is able to provide information on component orientation in THA without the use of mathematical formulas, and intra- and interobserver errors of 2 and 3°, respectively, have been reported [12–14]. The technique allows precise measurement of the version of the stem, but variation in pelvic tilt in patient positioning influences the measurements of cup orientation [15–17]. In the present study, we obtained CT-scans postoperatively with the patient in supine position to measure the version of the stem and cup in patients who underwent a cementless THA to answer what is the range of anteversion currently achieved in cementless THA. Furthermore, we asked whether there were differences in component version according to gender, surgical approaches, diagnosis of primary or secondary osteoarthritis or as compared the native anteversion of the hip joint.

Patients and methods

Patients

The study was approved by the local ethical committee and performed in accordance with the ethical standards of the 1964 Declaration of Helsinki as revised in 2000. It was prospectively performed in 91 patients (91 hips) who underwent primary cementless THA. There were 53 women and 38 men, and 17 had previously been operated in the other hip with prosthesis. The reason for surgery was primary osteoarthritis in 60 hips, and secondary osteoarthritis due to developmental dysplasia of the hip in 29 and Legg-Calvé-Perthes disease in two hips. The mean age at the time of surgery was 55.6 ± 16.5 years (range, 21 to

90 years). The age of the patients with primary osteoarthritis (59.5 ± 17.3 years) was significantly higher ($P < 0.001$) than the age of the patients with secondary osteoarthritis (48.8 ± 11.6 years).

Five senior surgeons at our hospital operated the 91 patients. A lateral approach to the hip was used in 40 cases, and a posterior approach was used in 51 cases. In all patients we used cementless replacement with a porous coated hemispherical press fit cup (Trilogy, Zimmer, Warsaw, IN, USA) and a hydroxyapatite coated straight and rectangular press fit stem (Corail, DePuy, Saint Priest, France). The cup was inserted first then the stem. We used cup sizes from 48 to 60 and stem sizes from 9 to 14. As a standard we aimed to obtain femoral anteversion of 10 to 30°, acetabular anteversion of 10 to 30° and a combined anteversion of 25 to 55°. Cup position was obtained with the aid of an acetabular cup impactor-positioner provided with the implant manufacturer. Stem position was obtained with the knee flexed 90° and the leg as the reference for anteversion. In all cases we used elevated liners to provide optimal femoral head coverage and we used a ceramic head with diameter 28 mm.

Methods of assessment

At 3 months postoperatively, and after informed consent in all patients, acetabular and femoral component version was measured using a General Electric LightSpeed Pro 16 (Milwaukee, WI, USA). Three single slices, 5 mm of thickness, were made through the centre of the femoral head, the middle of the femoral neck and just above the lesser trochanter, respectively. Another slice was performed in the knee region at the level of the femoral condyles. Femoral component version was calculated as the angle between a line from the head of the femoral prosthesis to the centre of the proximal femoral diaphysis; and a line connecting the posterior aspect of the medial and lateral femoral condyles, respectively (Fig. 1). We defined acetabular component version as the angle between a line connecting the lateral anterior and posterior margins of the acetabular component and the sagittal plane defined as the plane perpendicular to a line connecting two identical points on either side of the pelvis.

Descriptive statistics used mean, standard deviation and ranges. Differences between groups were tested using a two-sample *t*-test. $P < 0.05$ was considered significant. We also calculated Pearson's correlation coefficient (*r*).

Results

The femoral component version as measured from the CT-scan ranged from 17° of retroversion to 60° of anteversion with a mean of 23.0 ± 11.8 ° (Fig. 2). The anteversion of 63 (69.2%) of the femoral components were within the target zone of 10 to 30°, while nine (9.9%) of components were

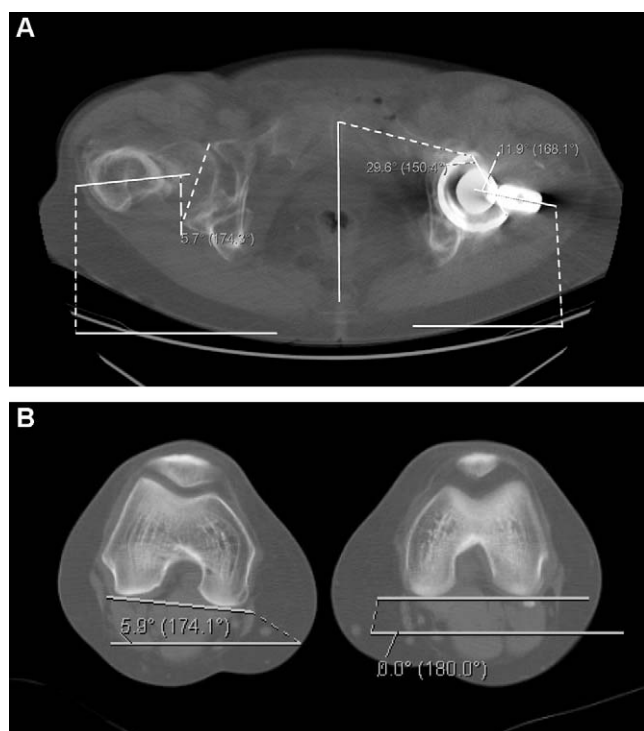


Figure 1 Femoral component version calculated as the angle between a line from the head of the femoral prosthesis to the centre of the proximal femoral diaphysis (A); and a line connecting the posterior aspect of the medial and lateral femoral condyles (B) (11.9° for the current case). Acetabular component version defined as the angle between a line connecting the lateral anterior and posterior margins of the acetabular component and the sagittal plane defined as the plane perpendicular to a line connecting two identical points on either side of the pelvis (A) (29.6° for the current case).

below the target zone (surgically overestimated) and 19 (20.9%) were above the target range and thus was surgically underestimated. There were no significant differences in femoral component version according to gender, surgical

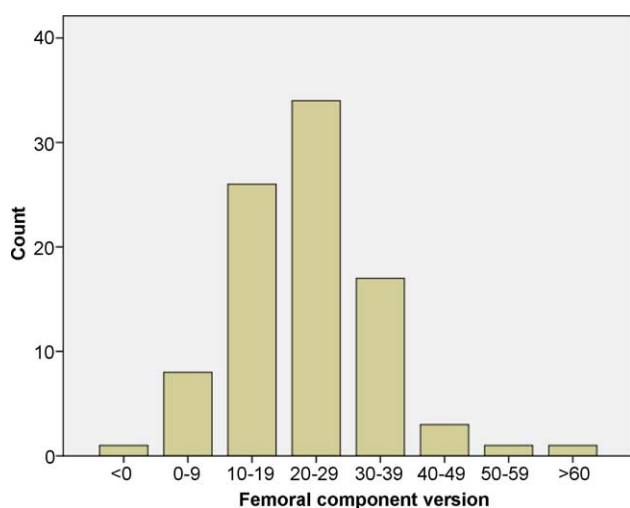


Figure 2 Distribution of femoral component version in 91 patients operated with cementless total hip arthroplasty.

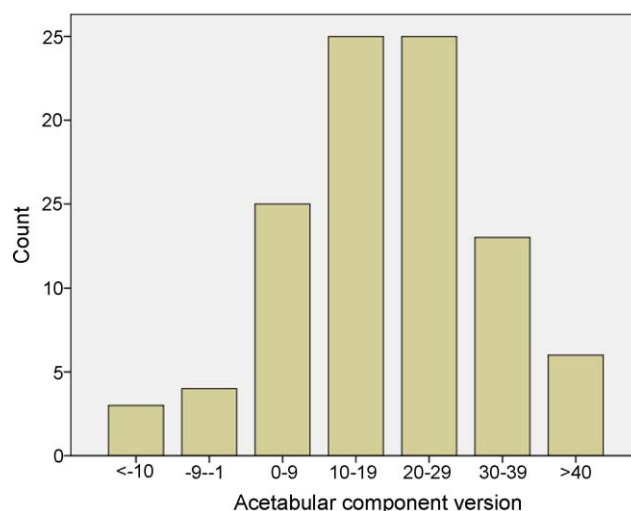


Figure 3 Distribution of acetabular component version in 91 patients operated with cementless total hip arthroplasty.

approaches or diagnosis of primary or secondary osteoarthritis (Tables 1–3). The native femoral version in the 74 patients with unilateral THA ranged from 6° of retroversion to 57° of anteversion with a mean of $23.9 \pm 11.6^\circ$, which was not significantly different from the femoral component version (Table 4). Moreover, there was no correlation between the stem and native versions ($r=0.132$).

The acetabular component version ranged from 28° of retroversion to 46° of anteversion with a mean of $18.5 \pm 13.7^\circ$ (Fig. 3). The anteversion of 53 (58.2%) of the acetabular components were within the target zone of 10 to 30°, while 22 (24.2%) were below the target zone and thus was surgically overestimated and 16 (17.6%) were above the target range and thus was surgically underestimated. The version of the acetabular component was less in the male patients as compared to the females ($P=0.018$), but there were otherwise no significant differences between approaches or patients with primary or secondary osteoarthritis. The native acetabular version ranged from 8° of retroversion to 35° of anteversion with a mean of $16.3 \pm 7.5^\circ$, which was not significantly different from the component version. Moreover, there was no correlation between the cup and native acetabular versions ($r=0.109$).

The combined version ranged from 18° of retroversion to 101° of anteversion with a mean of $41.6 \pm 18.9^\circ$ (Fig. 4). Fifty-five hips (60.4%) were within the target zone of 25 to 55°, while 13 (14.3%) were below the target zone and 23 (25.3%) were above the target zone. The combined version of the components was less in the male patients as compared to the females ($P=0.05$), but there were otherwise no significant differences between approaches or patients with primary or secondary osteoarthritis. The native combined version ranged from 2° of retroversion to 79° of anteversion with a mean of $40.5 \pm 14.4^\circ$, which was not significantly different from the combined component version. Moreover, there was no correlation between the combined prosthetic and native versions ($r=0.108$).

Table 1 Femoral component version, acetabular component version and combined version in cementless total hip arthroplasty in relation to gender.

Version	Females	Males	P-value
Femoral component	23.5 ± 12.9 (−17–60)	22.4 ± 10.1 (2–48)	0.685
Acetabular component	21.4 ± 14.4 (−28–46)	14.6 ± 11.8 (−21–37)	0.018
Combined	44.9 ± 20.3 (−18–101)	37.0 ± 15.9 (−6–66)	0.05

Values are mean ± SD (range).

Table 2 Femoral component version, acetabular component version and combined version in cementless total hip arthroplasty in relation to lateral (modified Hardinge) or posterior approaches.

Version	Lateral	Posterior	P-value
Femoral component	23.4 ± 14.5 (−17–60)	22.8 ± 9.4 (1–51)	0.785
Acetabular component	18.4 ± 13.1 (−15–41)	18.6 ± 14.3 (−28–46)	0.951
Combined	41.9 ± 20.0 (1–101)	41.4 ± 18.2 (−18–73)	0.900

Values are mean ± SD (range).

Table 3 Femoral component version, acetabular component version and combined version and combined version in cementless total hip arthroplasty in relation to primary or secondary osteoarthritis.

Version	Primary	Secondary	P-value
Femoral component	23.7 ± 10.3 (−17–48)	23.8 ± 12.1 (0–60)	0.970
Acetabular component	18.0 ± 13.7 (−28–42)	19.6 ± 13.4 (−15–46)	0.619
Combined	41.8 ± 18.1 (−18–74)	43.4 ± 19.5 (9–101)	0.699

Values are mean ± SD (range).

The patients have been followed for 2 years with no cases of dislocations or revisions. Furthermore, there were no cases with a leg length discrepancy above 2 cm.

Discussion

Successful THA relies on an accurate placement of the femoral and acetabular components, particular with respect to version. The generally accepted combined anteversion for THA has a safe zone from 25 to 50° (mean: 37 ± 12°) [18,19], with less combined anteversion in men than in women [5,8,20]. We found that in primary cementless THA using straight stem and hemispherical cup, the components anteversion was not significantly different from the native anteversion of the hip joint, but there was a wide range of component versions, and there were no correlations to the native versions.

The strength of our study is the experience of participating surgeons, and in all cases we used the same type of prosthesis. It has been shown that senior surgeons do better than residents, and different types of prostheses may influence the results [21]. Different surgical approaches (anterolateral and posterolateral) were used with the same results, and our results could be compared to the native anteversion of the hip. On the other hand, there are certain limitations to our study. We used a straight stem, and the precision of stem orientation could have been improved with a curved stem that better followed the anatomy of the proximal femur. In line with this, our results cannot automatically be transferred to cemented stems. Also, CT-scan studies of cup positioning should be interpreted with caution because there are variations of the pelvic orientation depending on patient positioning and there are different conventions used to describe the cup orientation [15–17,22]. Therefore, we emphasize that our results relies on CT-scan investigations with the patient in the supine position.

Table 4 Anatomical (native) femoral, acetabular and combined version in relation to gender.

Version	Females	Males	P-value
Femoral	24.1 ± 11.4 (−6–57)	23.6 ± 11.9 (2–53)	0.830
Acetabular	17.3 ± 8.5 (−8–35)	15.1 ± 5.8 (7–26)	0.201
Combined	42.0 ± 13.8 (−2–74)	38.7 ± 15.2 (10–79)	0.338

Values are mean ± SD (range).

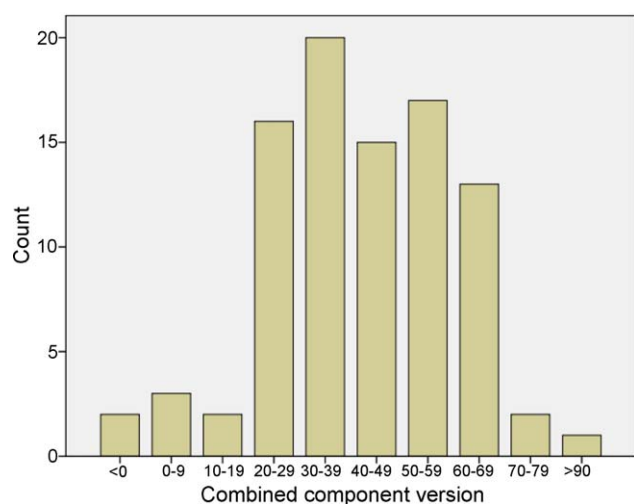


Figure 4 Distribution of combined component version in 91 patients operated with cementless total hip arthroplasty.

In our patients the femoral component version was underestimated more than twice as frequently as it was overestimated. In cementless THA the anteversion of the femoral component tends to be dictated by the shape of the proximal femur. A so-called “best fitting” straight-stemmed femoral component must negotiate the twist and bow of the proximal femur. Therefore, there may be a difference between the anteversion of the femoral prosthesis and the native anteversion of the femoral neck. This may especially be the case in patients with developmental dysplasia of the hip. However, in our series there were no significant differences in femoral component orientation between the patients with primary osteoarthritis and those with osteoarthritis secondary to developmental dysplasia of the hip.

In opposite to femoral component orientation, the acetabular component version was overestimated more frequently than it was underestimated. A reason may be that CT-scan in the lying position leads to retroversion of the cup relative to the standing position. In a previous study on freehand cup positioning, a tendency to underestimate the anteversion of the acetabular component was reported [21]. However, the study was performed with standardized X-rays and therefore cannot be directly compared to our study. One comparable study is that of Saxler et al. [23] who showed, in a retrospective CT-controlled design, that only 27 out of 105 cups (26%) were placed within the safe zone of Lewinnek. In a second study, Digioia et al. [24], used a specific mechanical acetabular alignment guide, and the results were controlled preoperatively with a hip navigation system. In 74 hips, only 22% of the cups were placed within the Lewinnek's safe zone [24]. Compared with these two studies, our data demonstrate better accuracy of cup positioning.

In a previous study [12] it is found that femoral and acetabular anteversion was overestimated with a posterior as compared to a lateral approach. It was suggested this was due to the theoretical risk of posterior dislocation with a posterior approach. In our study we found no differences in component orientation between a posterior and lateral

approach. With both approaches many cups were outside the intended range of anteversion.

Malposition of the acetabular cup has been considered a most important factor for dislocation of a total hip prosthesis. Coventry et al. [25] found a significant association between acetabular retroversion and posterior dislocation. On the other hand, Lewinnek et al. [4] reported a higher incidence of anterior dislocations in THA with more than 25° of acetabular component anteversion. Then, both excessive anteversion and retroversion should be avoided to prevent dislocation. However, the risk factors that predispose to dislocation are multivariate and include patient-related, operative, and implant design variables [26]. With a follow-up of 2 years, we had no cases of dislocation. The literature suggests that more than half of all dislocations after THA occur within the first 3 months after surgery, more than three quarters within one year [27], and one series demonstrated that 70% of dislocations occurred within the first month after surgery [28]. Our results thereby underline that malpositioning of the components is only one of many factors for dislocation. It has been shown that bigger head significantly reduces the rate of dislocation [29]. We used a rather small head, but malpositioning and the use of a small head in our series may have been compensated for by the elevation of the polyethylene insert.

When we perform THA, we start with the acetabular component, accepting the concept of combined component anteversion to prevent dislocation. With inappropriate acetabular anteversion, adjustment must be done on the femoral side. However, the anatomy of the proximal femur may restrict the anteversion of a cementless stem, and this may compromise the combined anteversion. In our study, only 60% were within the target ranges of the combined component anteversion. In line with this, some authors have recommended preparing the femur first and then adjusting the position of the cup to that of the stem to improve stability and reduce impingement [18].

Our measurements of normal femoral and acetabular anteversion are similar to those measured by others. Sugano et al. [30] cite native femoral anteversion to be $20 \pm 9^\circ$, and Stem et al. [31] report native acetabular anteversion to be $23 \pm 6^\circ$. The acetabular anteversion in males was reported to be about 3° less than in females. We also found that the native acetabular anteversion was less in males than in females, but not significantly. A tendency to follow the native anatomy can explain the higher acetabular component anteversion in females than in males. Only one previous study has correlated the component versions with native versions [9], and like us, they found poor correlations. A problem is that a safe component zone is not reflected in the patient's anatomy. Safe zones are statistical results of clinical, radiological and anatomical studies on different patient cohorts in relation to complications after THA. The use of safe zones as target for implant positioning may be in conflict with variations in the patient's anatomy. However, several studies have shown that the use of navigation systems may improve the placement of the acetabular component compared with that achieved with conventional freehand implantation. In an experimental approach, Jolles et al. [32] showed that computer-assisted methods are more accurate than traditional methods of cup positioning, and in a clinical study by Parratte and Argenson [33],

computer-assisted navigation significantly reduced the number of acetabular cup outliers. These results are in agreement with a prospective, randomized clinical study performed by Kalteis et al. [34]. Acetabular components were implanted either freehand ($n=30$), using CT-based ($n=30$) or imageless navigation ($n=30$). The position of the component was determined postoperatively on CT-scans. With conventional freehand placement of the acetabular cup, 14 of the 30 cups were within the safe zone of Lewinnek. After computer-assisted and imageless navigation, 25 and 28 respectively of the 30 acetabular components were positioned within this zone. No significant differences were observed between CT-based and imageless navigation. However, the use of navigation for THA adds costs and surgical time to the procedure and therefore must be an integral part of the operating theatre. The use of navigation systems, then, has to be balanced against many other different aspects to reduce the rate of impingement and dislocations as well as clinical outcomes.

Conclusion

Our study shows that intraoperative estimation of femoral and acetabular anteversion by a cup impactor-positioner and the knee flexed 90° for femoral reference in many cases is inadequate in cementless THA. In relation to the intended range of 10 to 30° anteversion of the components, femoral anteversion was surgically underestimated while acetabular anteversion was surgically overestimated. Altogether, about 40% of the cases were outside the accepted range of 25 to 55° of combined anteversion, but malposition was compensated for by elevated liners to provide optimal femoral head coverage.

Disclosure of interest

The authors declare that they have no conflicts of interest concerning this article.

References

- [1] Hassan DM, Johnston GHF, Dust WNC, Watson G, Dolovich AT. Accuracy of intra-operative assessment of acetabular prosthesis placement. *J Arthroplasty* 1998;13:80–4.
- [2] Kristiansen B, Jorgensen L, Holmich P. Dislocation following total hip arthroplasty. *Arch Orthop Trauma Surg* 1985;103:375–7.
- [3] Kummer FJ, Shah S, Iyer S, DiCesare PE. The effect of acetabular cup orientations on limiting hip rotation. *J Arthroplasty* 1999;14:509–13.
- [4] Lewinnek GE, Lewis JL, Tarr R, Compere CL, Zimmerman JR. Dislocations after total hip replacement arthroplasties. *J Bone Joint Surg Am* 1978;60:217–20.
- [5] Dorr LD, Malik A, Wan Z, Long WT, Harris M. Precision and bias of imageless computer navigation and surgeon estimates for acetabular component position. *Clin Orthop Relat Res* 2007;465:92–9.
- [6] Dorr LD, Malik A, Dastane M, Wan Z. Combined anteversion technique for total hip arthroplasty. *Clin Orthop Relat Res* 2009;467:119–27.
- [7] Pierchon F, Pasquier G, Cotten A, Fontaine C, Clarisse J, Duquenois A. Causes of dislocation of total hip arthroplasty. CT study of component alignment. *J Bone Joint Surg Br* 1994;76:45–8.
- [8] Yoshimine F. The safe-zones for combined cup and neck anteversions that fulfill the essential range of motion and their optimum combination in total hip replacements. *J Biomech* 2006;39:1315–23.
- [9] Bargar WL, Jamali AA, Nejad AH. Femoral anteversion in THA and its lack of correlation with native acetabular anteversion. *Clin Orthop Relat Res* 2010;468:527–32.
- [10] Goergen TG, Resnick D. Evaluation of acetabular anteversion following total hip arthroplasty: necessity of proper centering. *Br J Radiol* 1975;48:259–60.
- [11] Wolf A, DiGioia A, Mor A, Jaramaz B. A kinematic model for calculating cup alignment error during total hip arthroplasty. *J Biomech* 2005;38:2257–65.
- [12] Wines AP, McNicol D. Computed tomography measurement of the accuracy of component version in total hip arthroplasty. *J Arthroplasty* 2006;21:696–701.
- [13] Olivecrona H, Weidenhielm L, Olivecrona L, et al. A new CT method for measuring cup orientation after total hip arthroplasty: a study of 10 patients. *Acta Orthop Scand* 2004;75:252–60.
- [14] Hernandez RJ, Tachdjian MO, Poznanski AK, Dias LS. CT determination of femoral torsion. *AJR Am J Roentgenol* 1981;137:97–101.
- [15] Eddine TA, Migaud H, Chantelot C, Cotten A, Fontaine C, Duquenois A. Variations of pelvic anteversion in lying and standing positions: analysis of 24 control subjects and implications for CT measurements of position of a prosthetic cup. *Surg Radiol Anat* 2001;23:105–10.
- [16] Nishihara S, Sugano N, Nishii T, Ohzono K, Yoshikawa H. Measurements of pelvic flexion angle using three-dimensional computed tomography. *Clin Orthop Relat Res* 2003;411:140–51.
- [17] Blondel B, Parratte S, Tropiano P, Pauly V, Aubaniac JM, Argenson JN. Pelvic tilt measurement before and after total hip arthroplasty. *Orthop Traumatol Surg Res* 2009;95:568–72.
- [18] Malik A, Maheshwari A, Dorr LD. Impingement with total hip replacement. *J Bone Joint Surg Am* 2007;89:1832–42.
- [19] Widmer KH, Zurfluh B. Compliant positioning of total hip components for optimal range of motion. *J Orthop Res* 2004;22:815–21.
- [20] McKibbin B. Anatomical factors in the stability of the hip joint in the newborn. *J Bone Joint Surg Br* 1970;52:148–59.
- [21] Bosker BH, Verheyen CC, Horstmann WG, Tulp NJ. Poor accuracy of freehand cup positioning during total hip arthroplasty. *Arch Orthop Trauma Surg* 2007;127:375–9.
- [22] Yoon YS, Hodgson AJ, Tonetti J, Masri BA, Duncan CP. Resolving inconsistencies in defining the target orientation for the acetabular cup angles in total hip arthroplasty. *Clin Biomech (Bristol, Avon)* 2008;23:253–9.
- [23] Saxler G, Marx A, Vandevelde D, et al. The accuracy of free-hand cup positioning—a CT based measurement of cup placement in 105 total hip arthroplasties. *Int Orthop* 2004;28:198–201.
- [24] DiGioia 3rd AM, Jaramaz B, Plakseychuk AY, et al. Comparison of a mechanical acetabular alignment guide with computer placement of the socket. *J Arthroplasty* 2002;17:359–64.
- [25] Coventry MB, Beckenbaugh RD, Nolan DR, Ilstrup DM. 2012 Total hip arthroplasties: a study of postoperative course and early complications. *J Bone Joint Surg Am* 1974;56:273–84.
- [26] Sanchez-Sotelo J, Berry DJ. Epidemiology of instability after total hip replacement. *Orthop Clin North Am* 2001;32:543–52.
- [27] Woo RY, Morrey BF. Dislocations after total hip arthroplasty. *J Bone Joint Surg Am* 1982;64:1295–306.

- [28] Williams JF, Gottesman MJ, Mallory TH. Dislocation after total hip arthroplasty. Treatment with an above-knee hip spica cast. *Clin Orthop Relat Res* 1982;171:53–8.
- [29] Amlie E, Høvik Ø, Reikerås O. Dislocation after total hip arthroplasty with 28 and 32 mm femoral head. *J Orthop Traumatol* 2010;11:111–5.
- [30] Sugano N, Noble PC, Kamaric E. A comparison of alternative methods of measuring femoral anteversion. *J Comput Assist Tomogr* 1998;22:610–4.
- [31] Stem ES, O'Connor MI, Kransdorf MJ, Crook J. Computed tomography analysis of acetabular anteversion and abduction. *J Skeletal Radiol* 2006;35:385–9.
- [32] Jolles BM, Genoud P, Hoffmeyer P. Computer-assisted cup placement techniques in total hip arthroplasty improve accuracy of placement. *Clin Orthop Relat Res* 2004;426:174–9.
- [33] Parratte S, Argenson JN. Validation and usefulness of a computer-assisted cup positioning system in total hip arthroplasty. A prospective, randomized, controlled study. *J Bone Joint Surg Am* 2007;89:494–9.
- [34] Kalteis T, Handel M, Balthis H, Perlick L, Tingart M, Grifka J. Imageless navigation for insertion of the acetabular component in total hip arthroplasty: is it accurate as CT-based navigation? *J Bone Joint Surg Br* 2006;88:163–7.