

Imageless navigation for insertion of the acetabular component in total hip arthroplasty

IS IT AS ACCURATE AS CT-BASED NAVIGATION?

T. Kalteis,
M. Handel,
H. Bächis,
L. Perlick,
M. Tingart,
J. Grifka

*From Department of
Orthopaedic Surgery,
University of
Regensburg,
Germany*

In a prospective randomised clinical study acetabular components were implanted either freehand (n = 30) or using CT-based (n = 30) or imageless navigation (n = 30). The position of the component was determined post-operatively on CT scans of the pelvis.

Following conventional freehand placement of the acetabular component, only 14 of the 30 were within the safe zone as defined by Lewinnek et al (40° inclination SD 10°; 15° anteversion SD 10°). After computer-assisted navigation 25 of 30 acetabular components (CT-based) and 28 of 30 components (imageless) were positioned within this limit (overall $p < 0.001$). No significant differences were observed between CT-based and imageless navigation ($p = 0.23$); both showed a significant reduction in variation of the position of the acetabular component compared with conventional freehand arthroplasty ($p < 0.001$). The duration of the operation was increased by eight minutes with imageless and by 17 minutes with CT-based navigation.

Imageless navigation proved as reliable as that using CT in positioning the acetabular component.

Malposition of the acetabular component in total hip arthroplasty restricts the range of movement, is the most common cause of dislocation and can lead to increased and premature wear.¹⁻⁹ Assessing the correct amount of anteversion and abduction is essential to the assessment of short- and long-term outcomes in total hip arthroplasty. However, recent studies have shown that placement of the acetabular component within the safe zone with an inclination of 40° (SD 10°) and anteversion of 15° (SD 10°) as defined by Lewinnek et al,¹⁰ is not guaranteed when using the freehand technique of operation, even in the hands of an experienced surgeon.¹¹⁻¹³ Using mechanical alignment guides has not improved the accuracy of placement of the acetabular component significantly.¹⁴⁻¹⁷

CT-based navigation has enabled significant improvement in the accuracy of positioning of the acetabular component,^{11,12,18,19} but has not become established as routine because of the additional operative time, expense and exposure to radiation.

Imageless navigation may provide a viable alternative. In this procedure alignment of the implant is based only on landmarks (anterior superior iliac spines and pubic tubercles) acquired intra-operatively by the surgeon using a reference pointer. They provide the

basis for 'surgeon-defined anatomy' and are used to define the frontal pelvic plane. Additional pre- or intra-operative image acquisition is not required.

We undertook a prospective randomised study to see whether the accuracy of computer-assisted placement of the acetabular component, both CT-based and imageless, was significantly better than that obtained by the conventional technique. We also examined whether the accuracy of placement of the component using imageless navigation matched that which was CT-based.

Patients and Methods

This study was carried out following authorisation by the Institutional Ethical Board (No. 03/085) and the Federal Office for Radiation Protection (Z5-22462/2-2003-027). Preliminary data comparing the results of a freehand technique and imageless navigation have been reported in an earlier study.²⁰

Between August 2004 and June 2005, 99 patients requiring total hip arthroplasty for primary osteoarthritis were enrolled prospectively in this single-centre study. Exclusion criteria were arthritis secondary to hip dysplasia, post-traumatic deformities of the pelvis, or because a post-operative pelvic CT scan was required, age at the time of operation of less

■ T. Kalteis, MD,
Orthopaedic Surgeon
■ M. Handel, MD,
Orthopaedic Surgeon
■ H. Bächis, MD, Orthopaedic
Surgeon
■ L. Perlick, MD, Orthopaedic
Surgeon
■ M. Tingart, MD,
Orthopaedic Surgeon
■ J. Grifka, MD, Orthopaedic
Surgeon, Professor, Head of
Department
Department of Orthopaedic
Surgery
University of Regensburg,
Asklepios Klinikum Bad
Abbach, Kaiser-Karl V.-Allee
3, 93077 Bad Abbach,
Germany.

Correspondence should be
sent to Dr T. Kalteis; e-mail:
thomas.kalteis@klinik.uni-
regensburg.de

©2006 British Editorial
Society of Bone and
Joint Surgery
doi:10.1302/0301-620X.88B2.
17163 \$2.00

J Bone Joint Surg [Br]
2006;88-B:163-7.
Received 5 September 2005;
Accepted 11 October 2005

Table 1. Age, gender and body mass index (BMI) of the patients in the three study groups

	Freehand (n = 30)	CT-based (n = 30)	Imageless (n = 30)	p value
Age (yrs)				
Mean (SD; range)	64.7 (8.6; 50 to 79)	63.9 (8.6; 50 to 79)	63.1 (8.5; 50 to 77)	0.78
Sex				
Men:women	13:17	18:12	12:18	0.39
BMI (kg/m²)				
Mean (SD; range)	28.5 (4.1; 20 to 36)	27.8 (4.0; 21 to 42)	27.6 (3.7; 21 to 34)	0.63

than 50 years. After giving written consent to participate in the clinical and radiological study, the patients were assigned randomly by lot to one of the three groups: 1) conventional freehand hip arthroplasty, 2) CT-based navigated placement of the acetabular component, and 3) imageless navigated placement of the component.

Nine patients were withdrawn from the study. In four cases the acetabular trial component was insufficiently stable to ensure satisfactory fixation of the press-fit acetabular component, and cemented polyethylene acetabular components were used instead. In two cases of planned CT-based total hip arthroplasty, the reference points registered at operation could not be sufficiently well matched to the pre-operative planning to enable navigation. In the imageless navigation group, computer-assisted surgery was interrupted in three patients, once because the pelvic reference array became loose, and twice because the acetabular component model could not be generated accurately.

In accordance with the study protocol, additional patients were included until 30 had been operated on in each group and each had undergone a post-operative CT examination.

The mean age of the 90 patients (42 men, 48 women) was 63.9 years (50 to 79; SD 8.5). In 46 patients the right hip was affected and in 44 the left. The mean body mass index (BMI) of the patients was 28 (20 to 42; SD 3.9).

Surgical procedure. The surgery was performed by two senior consultants (JG, LP), both of whom operated on the same number of patients in each of the three groups. Both had familiarised themselves with computer-assisted surgery with more than 50 navigated total hip arthroplasties. All operations were performed with the patient supine using a modified transgluteal approach. Press-fit components (Pinnacle, DePuy, Warsaw, Indiana), and cement-free hydroxyapatite-coated stems (Corail; DePuy) were used. Our target acetabular component position for all patients was 45° inclination and 15° anteversion. Depending on the primary stability, deviations within the safe zone defined by Lewinnek et al¹⁰ were tolerated.

In the conventional surgery group, the acetabular components were placed freehand, without using mechanical or computerised alignment guides. CT-guided placement of the component was performed using the CT-based module of the VectorVision hip 3.0 system (BrainLAB, Heimstetten, Germany). Imageless navigation was performed

using the VectorVision hip 3.0 landmark-based module (BrainLAB).

Outcome measurement. The duration of each operation was recorded. To provide an indication of the level of peri-operative blood loss, the reduction in the haemoglobin level during the first 24 hours was assessed and the volume of blood collected in the suction drain was measured over the first 48 hours.

All 90 patients included in the study had a pelvic CT scan five to six weeks after operation. The position of the acetabular component was evaluated by an independent external institute (MeVisLab, MeVis, Bremen, Germany) with knowledge of the surgical technique. The position of the acetabular component was measured twice by two independent examiners on a 3D reconstruction of the pelvis using image-processing software (based on MeVisLab, MeVis).

The operative inclination and anteversion as defined by Murray²¹ were determined. The differences between the desired cup positions and that which was achieved were calculated.

In addition, the intra-operative inclination and anteversion documented by the screenshot software for the CT-based or imageless navigation systems were compared with the post-operative CT-based analyses to verify the accuracy of CT-guided and image-free navigation. In order to show the cup positions graphically with reference to the Lewinnek safe zone, the position of the cup after operation was converted to the radiological values for inclination and anteversion using the algorithm described by Murray.²¹

Statistical analysis. The percentage of procedures where the result was outside the Lewinnek safe zone was considered as the primary end-point of the study. It was hypothesised that the rate of malpositioning could be reduced from about 50% to below 15% using either type of navigation. Using standard assumptions ($\alpha = 0.05$ two-sided, power = 0.80, chi-squared test), at least 27 patients per group with adequate post-operative CT scans were required.

Statistical analysis was performed as three group comparisons using the chi-squared test for categorical data and analysis of variance (ANOVA) for continuous measurements. Only where statistical significance was found were pairwise comparisons of the groups performed.

Statistical analysis was performed using SPSS (version 12, SPSS Inc., Chicago, Illinois). Values for $p < 0.05$ were considered statistically significant.

Table II. Duration of conventional and computer-assisted total hip arthroplasty (THA), decrease in haemoglobin (Hb) per 24 hours, and volume of blood loss per 48 hours

	Freehand (n = 30)	CT-based (n = 30)	Imageless (n = 30)	p value
Mean duration of THA in mins (range)	75.1 (40 to 120)	92.0 (61 to 130)	82.6 (53 to 105)	0.002
Mean decrease in Hb/24 hours in mg/dl (range)	3.1 (1.5 to 5.7)	3.1 (0.9 to 4.4)	3.2 (0.4 to 5.5)	0.57
Mean blood loss/48 hours in ml (range)	399 (50 to 1090)	341 (50 to 950)	359 (20 to 730)	0.90

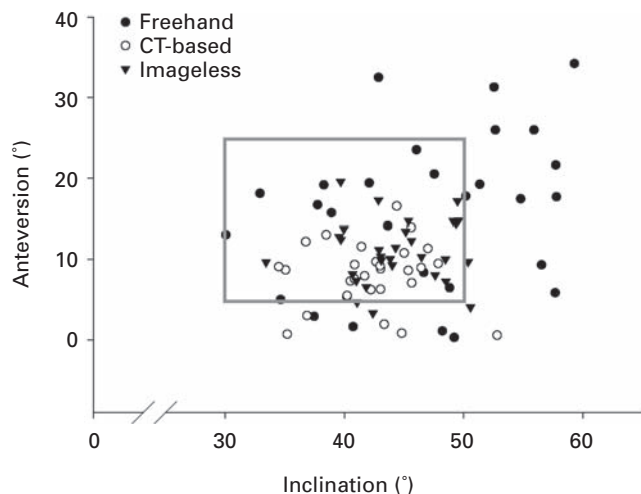


Fig. 1

Positions of the acetabular component relative to Lewinnek's safe zone (grey frame).

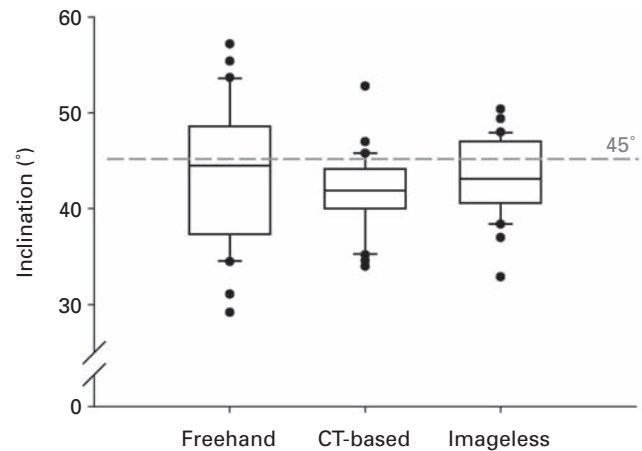


Fig. 2

Inclination of the acetabular component following freehand, CT-based and imageless navigation. The boundaries of the boxes indicate the 25th and the 75th percentiles, the lines within the boxes mark the mean values. Whiskers above and below the box indicate the 90th and the 10th percentiles. Overall $p = 0.27$.

Results

There were no significant differences in demographic data between the three study groups (Table I).

The operation time was increased by 17 minutes when using CT-based navigation compared with the conventional technique ($p < 0.001$) and by eight minutes with imageless navigation ($p = 0.11$). Imageless navigation was significantly faster than the CT-based method ($p = 0.046$) (Table II).

There were no significant differences between the three groups with regard to the decrease in haemoglobin or blood drainage (Table II).

No patient suffered a neurovascular complication or infection in the first six weeks after surgery. One who had conventional surgery had a dislocation of the hip five weeks after operation. Using the conventional technique, 16 of the 30 components (53%) were outside Lewinnek's scale zone of 40° inclination (SD 10°) and 15° anteversion (SD 10°). In the CT-based group, five of the 30 components (17%) were outside the safe zone, as were two of the 30 components (7%) using imageless navigation (Fig. 1).

Compared with the results of the freehand procedure, both CT-based ($p = 0.003$) and imageless navigation ($p < 0.001$) resulted in a significant reduction in placements outside the safe zone, whereas no significant difference was seen between CT-based and imageless navigated acetabular component insertion ($p = 0.23$).

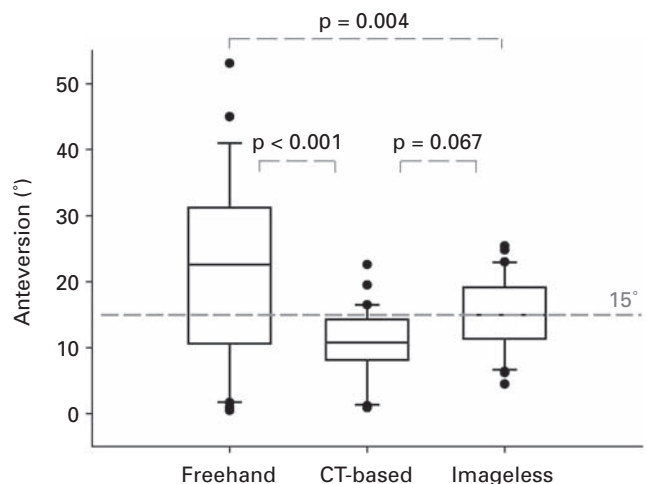


Fig. 3

Anteversion of the acetabular component following freehand, CT-based and imageless navigation. The boundaries of the boxes indicate the 25th and the 75th percentiles, the lines within the boxes mark the mean values. Whiskers above and below the box indicate the 90th and 10th percentiles. Overall $p < 0.001$.

For conventional freehand acetabular component placement, the mean inclination was 43.7° (29° to 57°; SD 7.3°) and the mean anteversion was 22.2° (1° to 53°; SD 14.2°).

Table III. Deviations from the desired inclination of 45° and the desired anteversion of 15° using freehand placement of the acetabular component, CT-based navigation and imageless navigation

	Freehand (n = 30)	CT-based (n = 30)	Imageless (n = 30)	p value
Mean deviation from 45° inclination (°) (range)	6.1 (0 to 16)	4.2 (0 to 11)	3.6 (1 to 12)	0.015*
Mean deviation from 15° anteversion (°) (range)	13.0 (0 to 38)	5.3 (0 to 14)	4.2 (0 to 10)	< 0.001†

* freehand vs CT-based $p = 0.032$; freehand vs imageless $p = 0.004$; CT-based vs imageless $p = 0.44$

† freehand vs CT-based $p < 0.001$; freehand vs imageless $p < 0.001$; CT-based vs imageless $p = 0.51$

With CT-based placement, the mean inclination was 41.6° (34° to 53°; SD 4.0°) and the mean anteversion 10.7° (1° to 23°; SD 5.3°).

Acetabular components placed using imageless navigation had a mean inclination of 43.2° (33° to 50°; SD 4.0°) and a mean anteversion of 15.2° (5° to 25°; SD 5.5°).

The smaller variation in the positioning of the acetabular component between CT-based and imageless navigation compared with conventional freehand surgery was indicated by the lower standard deviations in the computer-assisted study groups, especially for anteversion (Figs 2 and 3). For both measurements there is a significant heterogeneity of variances ($p < 0.001$, Levene test).

The mean absolute deviation from our desired inclination (45°) as well as from the desired anteversion (15°) was significantly different ($p < 0.001$) (Table III). Again there was a significant heterogeneity of variances, with the highest variation of measurements in the freehand group. Both navigated procedures showed significantly lower deviations for inclination and anteversion compared with the conventional freehand operation technique ($p < 0.05$). No significant difference in deviation from the target position of the acetabular component was observed between CT-based and imageless navigation (Table III).

Comparing the angles of inclination and anteversion recorded by the CT-based navigation systems intra-operatively with the position of the acetabular component post-operatively, there was a deviation of 3° for inclination (0° to 9°; SD 2.6°) and 3.3° for anteversion (0° to 9°; SD 2.3°). For imageless navigation, a deviation of 2.9° for inclination (0° to 10°; SD 2.2°) and 4.2° for anteversion (0° to 13°; SD 3.3°) was found. No significant difference was seen between the accuracy of CT-based and of imageless navigation ($p = 0.24$ for inclination, $p = 0.91$ for anteversion).

Discussion

Malpositioning of the acetabular component in total hip arthroplasty may result in a limited range of movement, joint luxation and increased wear, reducing the survival of the prosthesis.¹⁻⁹ The aim of this randomised prospective study was to investigate the results after CT-based and imageless navigated implantation of the cup and to compare the results with those obtained using the freehand technique.

Over 50% of the acetabular components implanted using the freehand technique were outside Lewinnek's safe zone. The high variability and imprecision of freehand

placement shown in this study correspond with results previously published. In a multicentre study carried out by Saxler et al,¹³ only 26% of the acetabular components positioned using the freehand method were within the safe zone. The authors reported a mean inclination of 45.8° (23° to 71°; SD 10.1°) and a mean anteversion of 27.3° (-23° to 59°; SD 15.0°) measured on CT scans taken after implanting the acetabular component freehand. Hassan et al¹⁴ found that 42% of the components were positioned outside the safe zone, despite the use of mechanical alignment guides. DiGioia et al¹⁵ found that 78% of components implanted freehand were malpositioned as judged by intra-operative computer-assisted measurements. These inaccuracies can be significantly reduced by CT-based computer-assisted surgery.^{11,12,18,19}

In this study, the computer-assisted total hip arthroplasty was performed with the patient supine. CT-based or imageless navigation can also be performed with the patient in the lateral position, either using the so called 'flip-technique', referencing the bony landmarks to determine the anterior pelvic plane in the supine position, with implant insertion after relocation of the patient to the lateral position, or by slightly changing the lateral position for referencing to be able to acquire the contralateral anterior superior iliac spine. However, the accuracy of CT-based or imageless navigation in THA performed in the lateral position needs to be determined in additional studies.

Imageless navigation, also known as kinematic or landmark-based navigation, is another option which has not previously been verified against CT-based navigation. We have shown that placement of the acetabular component using imageless navigation is as accurate as the CT-based method in patients with primary osteoarthritis. Both techniques significantly reduce the variation in the positioning of the component compared with the conventional freehand method. The clinical results of imageless navigation which we obtained correspond with those of previous *in vitro* studies.^{16,17} CT-based navigation might still have some advantages over the imageless system in patients with abnormal anatomy such as hip dysplasia, post-traumatic deformities or in revision procedures,²² but this requires further investigation.

It is not always possible to maintain the preferred inclination and anteversion even with computer-assisted techniques. Deviations in the position of the acetabular component can arise during impaction of press-fit components, because of under-reaming or of oversizing.¹¹ How-

ever, whereas these problems are not usually perceived or their extent estimated with a conventional surgical technique, navigational support enables constant monitoring of the orientation of the cup. The surgeon can then assess whether any deviation is acceptable or whether the position should be corrected.

Evaluation of the position of the acetabular component on post-operative CT scans is superior to standard radiographic analysis, where determination of anteversion may result in significant errors.²³⁻²⁵

Imageless navigation is a reliable technical tool which significantly reduces the variation and inaccuracies of conventional freehand placement of the acetabular component in hip arthroplasty and is as accurate as the CT-based method. Further studies are required to evaluate the accuracy of navigating femoral implants, and to examine whether the improvement in acetabular placement achieved by navigation reduces post-operative complications and increases mid- and long-term survival of the implant in arthroplasty of the hip.

Supplementary Material



A further opinion by Professor Rémy Nizard is available with the electronic version of this paper on our website at www.jbjs.org.uk

Statistical analysis was performed by Rolf Lefering MD, Institute for Research in Operative Medicine, University Witten-Herdecke, Germany. The navigation system used in this study was provided by BrainLAB, Heimstetten, Germany.

No benefits in any form have been received or will be received from a commercial party related directly or indirectly to the subject of this article.

References

1. McCollum DE, Gray WJ. Dislocation after total hip arthroplasty: causes and prevention. *Clin Orthop* 1990;261:159-70.
2. Pierchon F, Pasquier G, Cotton A, et al. Causes of dislocation of total hip arthroplasty: CT study of component alignment. *J Bone Joint Surg [Br]* 1994;76-B:45-8.
3. Paterno SA, Lachiewicz PF, Kelley SS. The influence of patient-related factors and the position of the acetabular component on the rate of dislocation after total hip replacement. *J Bone Joint Surg [Am]* 1997;79-A:1202-10.
4. Del Schutte H Jr, Lipman AJ, Bannar SM, et al. Effects of acetabular abduction on cup wear rates in total hip arthroplasty. *J Arthroplasty* 1998;13:621-6.
5. Kennedy JG, Rogers WB, Soffe KE, et al. Effect of acetabular component orientation on recurrent dislocation, pelvic osteolysis, polyethylene wear, and component migration. *J Arthroplasty* 1998;13:530-4.
6. Kummer FJ, Shah S, Iyer S, DiCesare PE. The effect of acetabular cup orientations on limiting hip rotation. *J Arthroplasty* 1999;14:509-13.
7. D'Lima DD, Urquhart AG, Buehler KO, Walker RH, Colwell CW Jr. The effect of the orientation of the acetabular and femoral components on the range of motion of the hip at different head-neck ratios. *J Bone Joint Surg [Am]* 2000;82-A:315-21.
8. Jolles BM, Zangger P, Leyvraz PF. Factors predisposing to dislocation after primary arthroplasty: a multivariate analysis. *J Arthroplasty* 2002;17:282-8.
9. DeWal H, Su E, DiCesare PE. Instability following total hip arthroplasty. *Am J Orthop* 2003;32:377-82.
10. Lewinnek GE, Lewis JL, Tarr R, Compere CL, Zimmerman JR. Dislocations after total hip replacement arthroplasties. *J Bone Joint Surg [Am]* 1978;60-A:217-20.
11. DiGioia AM, Jaramaz B, Blackwell M, et al. The Otto Aufranc Award: image-guided navigation system to measure intraoperatively acetabular implant alignment. *Clin Orthop* 1998;355:8-22.
12. Leenders T, Vandevelde D, Mahieu G, Nuyts R. Reduction in variability of acetabular cup abduction using computer-assisted surgery: a prospective and randomized study. *Comput Aided Surg* 2002;7:99-106.
13. Saxler G, Marx A, Vandevelde D, et al. The accuracy of free-hand cup positioning: a CT based measurement of cup placement in 105 total hip arthroplasties. *Int Orthop* 2004;28:198-201.
14. Hassan DM, Johnston GH, Dust WN, Watson G, Dolovich AT. Accuracy of intra-operative assessment of acetabular prosthesis placement. *J Arthroplasty* 1998;13:80-4.
15. DiGioia AM, Jaramaz B, Plakseychuk AY, et al. Comparison of a mechanical acetabular alignment guide with computer placement of the socket. *J Arthroplasty* 2002;17:359-64.
16. Jolles BM, Genoud P, Hoffmeyer P. Computer-assisted cup placement techniques in total hip arthroplasty improve accuracy of placement. *Clin Orthop* 2004;426:174-9.
17. Nogler M, Kessler O, Prassl A, et al. Reduced variability of acetabular cup positioning with use of an imageless navigation system. *Clin Orthop* 2004;426:159-63.
18. Jaramaz B, DiGioia AM 3rd, Blackwell M, Nikou C. Computer assisted measurement of cup placement in total hip replacement. *Clin Orthop* 1998;354:70-81.
19. Widmer KH, Grutzner PA. Joint replacement-total hip replacement with CT-based navigation. *Injury* 2004;35(Suppl 1):90-5.
20. Kalteis T, Handel M, Herold T, et al. Greater accuracy in positioning of the acetabular hip by using an image-free navigation system. *Int Orthop* 2005;29:272-6.
21. Murray DW. The definition and measurement of acetabular orientation. *J Bone Joint Surg [Br]* 1993;75-B:228-32.
22. Haaker R, Tiedjen K, Rubenthaler F, Stockholm M. Computer-assisted navigated cup placement in primary and secondary dysplastic hips. *Z Orthop Ihre Grenzgeb* 2004;141:105-11 (in German).
23. Herrlin K, Pettersson H, Selvik G. Comparison of two- and three-dimensional methods for assessment of orientation of the total hip prosthesis. *Acta Radiol* 1988;29:357-61.
24. Widmer KH. A simplified method to determine acetabular cup anteversion from plain radiographs. *J Arthroplasty* 2004;19:387-90.
25. Tannast M, Langlotz U, Siebenrock KA, et al. Anatomic referencing of cup orientation in total hip arthroplasty. *Clin Orthop* 2005;436:144-50.